

# Topical Effects of Glycolic Acid on Skin Histology of Albino Mice

MUHAMMAD AKRAM<sup>1</sup>, RUKHSANA JABEEN, NAZIA SIDDIQUE

## ABSTRACT

Aging is the continuous process that results in the thinning and dryness of skin. The number of epidermal cells decreases and their mitotic activity slows down. Different antiaging agents are used both topically and orally to reverse or stop age related changes in the skin. We conducted an experimental study to see the microscopic changes of topically applied antiaging agents on the skin. Sixty-four female Swiss albino mice were obtained and divided into control and experimental groups. Control group A was applied only aqua base cream to the dorsal skin while control group B was applied nothing on the skin and experimental group C was applied glycolic acid for six weeks duration on the dorsal skin surface. Reversibility of the treatment was also checked by applying the treatment only for six weeks and next six weeks no agent was applied. In experimental group C we found increased thickness of the two layers of skin as compared to controls. No permanent changes were produced. Our results suggested that glycolic acid is one of the better choices for treatment of anti aging.

**Keywords:** Glycolic acid, albino mice, skin

---

## INTRODUCTION

Skin is one of the important and the largest organs of the body, which clearly depicts the picture of aging process<sup>1-2</sup>. Skin aging may be time related or environment related. Time related aging is also called intrinsic aging results in wrinkling and dryness<sup>3</sup> of skin. Different environment related factors like sunlight, radiations, stress, poor intake, smoking and pollution are responsible for photoaging. The ultraviolet radiations (UVR) present in the sunlight are the most dangerous and results in the premature aging<sup>4</sup>.

Multiple results of aging are thinning of epidermis and dermis, reduced adherence of keratinocytes, less production of sebum, reduced number of sweat glands and flattened dermal papilla. All these changes result in wrinkling and skin dryness<sup>1-3</sup>. These days everyone is using some rejuvenating agent for beautifying their skin. Most of these people have reduced wrinkles and skin dryness problems as compared to others. Different rejuvenating agents are easily available in the market to the public. The effectiveness of different antiaging agents like lotions, creams and moisturizers is controversial, as many of these cosmetic products, have not undergone proper histological testing<sup>6</sup>.

Glycolic acid is a powerful anti-aging agent. It removes the dead cells and exposes newer cells so improving the outlook of skin. It is superficial peeling

agent and mostly used in combination with other topical agents like retinol and salicylic acid<sup>7,8</sup>. We studied its histological effects on the skin of albino mice.

## MATERIALS AND METHODS

This study was conducted at the Postgraduate Medical Institute (PGMI), Lahore. This randomized control trial was conducted by using Swiss albino mice as an experimental model. Sixty four female albino mice were obtained from the VRI, Lahore. The selection criteria were 9-12 months age and 25-30 grams weight. They were housed in experimental research laboratory of the Postgraduate Medical Institute (PGMI), Lahore, under controlled conditions<sup>3</sup>. They were fed on standard mice diet and water ad libitum. After acclimatization of animals for one week, procedure was started. Balloting method was use to divide the Swiss albino mice randomly into different groups. Each group had 32 mice and the two sub groups in each group had 16 mice each. Thirty two mice were selected at random from treated animals eight from each sub group whose untreated dorsal skin was taken as untreated control group B. After Six weeks subgroups 1 were sacrificed and after twelve weeks subgroups 2 were sacrificed.

## RESULTS

All the data was entered and analyzed by SPSS version 17.0. Thickness of epidermis and dermis was presented as Mean±SD. Thickness of Epidermis after six and twelve weeks were compared by paired t-test to find out p-value (Table 1; Fig.1-5).

---

<sup>1</sup>Associate Professor, Dept of Anatomy, Sargodha Medical College

<sup>2</sup>Lecturer, Department of Anatomy, Sargodha Medical College

<sup>3</sup>Assistant Professor, Department of Anatomy, Fatima Memorial Hospital & College of Medicine & Dentistry

Correspondence to Dr. Muhammad Akram, Email: drakramch@yahoo.com

Table 1: Comparison of epidermal thickness in different experimental and control groups after six and twelve weeks.

Groups	Mean± SD		t-value	p-value
	6 weeks	12 weeks		
A	20.38±1.13	19.56±1.92	1.03	0.319
B	20.13±2.05	19.13±1.60	1.09	0.295
C	44.81±3.51	21.06±1.64	17.33	0.000*

Paired t-test was used to calculate p-value  
\*p-value<0.001 significant

Thickness of dermis after six and twelve weeks in different groups was presented by mean±SD. Paired t-test was used to compare them and find out p-value (Table 2; Fig.1-6).

Fig 1: Bar graph showing the comparison of epidermal thickness in different groups after six and twelve weeks. SD is shown by I and \* shows significance.

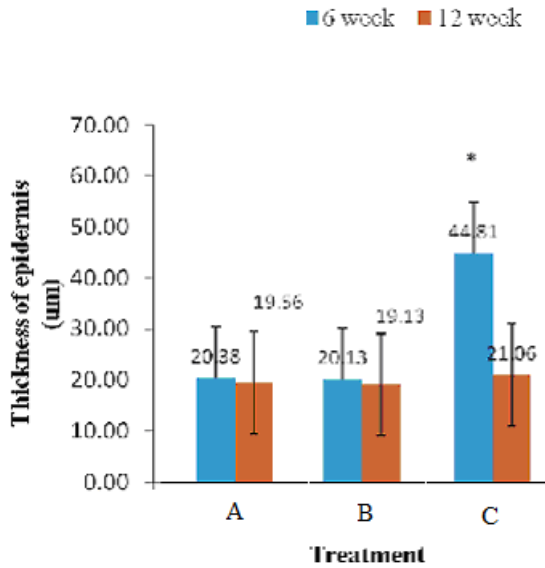


Table.2: Comparison of dermal thickness in different groups after six and twelve weeks.

Groups	Mean± SD		t-value	p-value
	6 weeks	12 weeks		
A	204.88±11.64	202.00±15.19	0.42	0.677
B	205.00±17.38	200.81±8.73	0.61	0.556
C	226.94±10.34	209.06±17.12	2.53	0.024*

Paired t-test was used to calculate p-value.\*p-value<0.05 significant

Fig 2: Bar graph showing the comparison of dermal thickness in different groups after six and twelve weeks. SD is shown by I and \* shows significance.

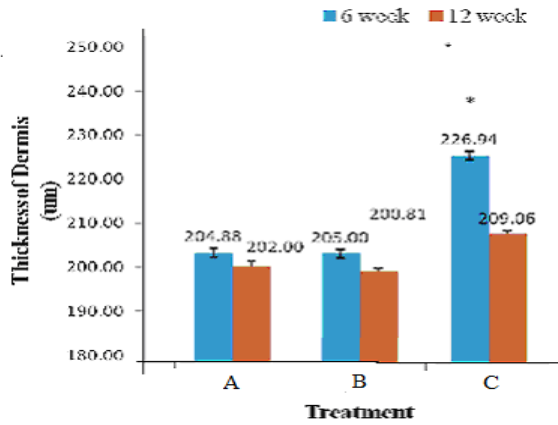


Fig.3. Photomicrograph of the skin of vehicle control group A after 6 weeks, showing separation of keratin layer (purple arrow) and minimal changes in thickness of epidermis (green arrow). H & E stain X, 400.

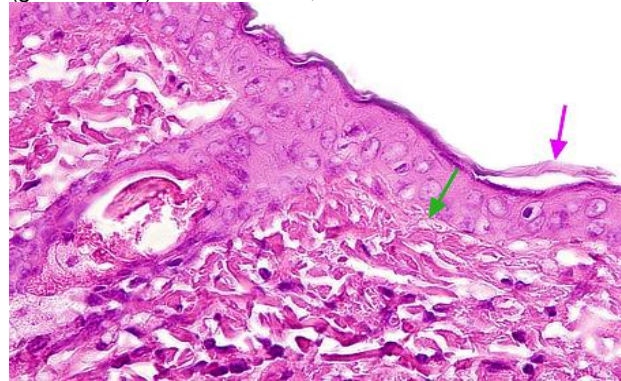


Fig.4. Photomicrograph of the skin from the control group B without any topical treatment after 6 weeks, showing epidermis (green arrow), dermal collagen bundles (red arrow) and hair follicles are also visible. H & E stain X, 400.

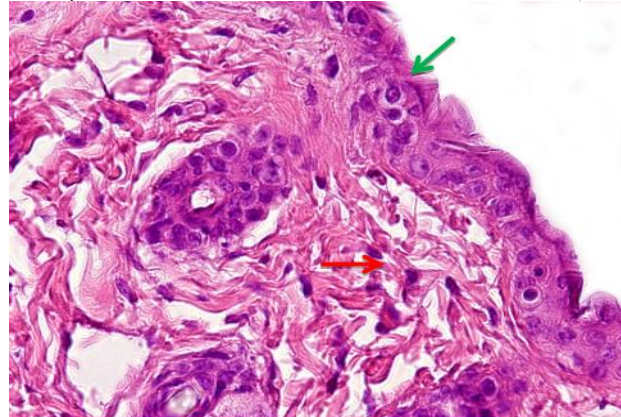


Fig.5. Photomicrograph of the skin of group C (glycolic acid) after 6 week, showing increased thickness of epidermis (green arrow) and thick collagen bundles (yellow arrows) and prominent fibroblasts in dermis. H & E stain X, 400.

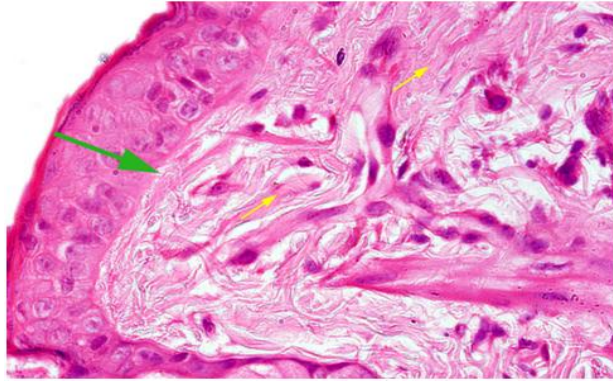
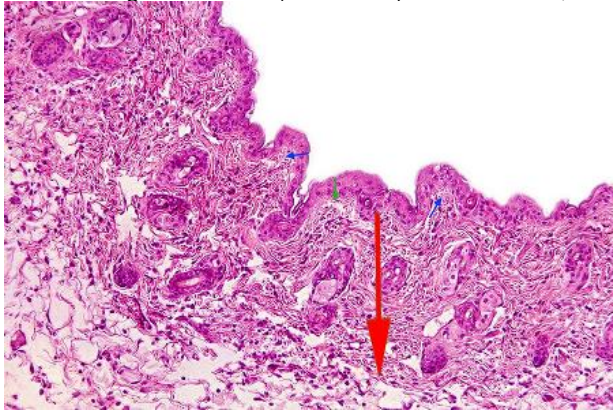


Fig.6. Photomicrograph of skin of group C after 12 weeks, showing reduced thickness of epidermis (green arrow), dermis with hair follicles and sebaceous glands (red arrow) and rete ridges of dermis (blue arrow). H & E stain X, 200.



## DISCUSSION

Aging is a process that continues with time sooner or later. Both environmental and time related aging affect the skin. Skin of face is affected more with the aging process<sup>8</sup>. The two layers of skin are epidermis and dermis. Epidermis is epithelial layer consisting of five strata. The stratum basale and stratum spinosum are collectively called stratum germinativum. The epidermis is separated from the dermis by basement membrane. Dense irregular connective tissue is the major component of dermis<sup>9,10</sup>.

In our study, epidermal and dermal thickness of albino mice skin in experimental group after 6 week is significantly increased as compared to control groups. Similar results were also seen with the studies conducted by Bhattacharyya and Dhar<sup>3,11</sup>. The number of lamellar bodies and layers of stratum corneum also increased with glycolic acid application. Basal cell proliferation is mainly responsible for epidermal thickness. Epidermal thickness and more hyperkeratosis are the results of glycolic acid<sup>7</sup>.

There is also increased proliferation of fibroblast resulting in greater thickness of dermis. The

improvement in the different aspects of skin in human studies were also clinically observed by use of glycolic acid. Multiple skin problems regarding aging like wrinkling and dryness were also studied in the human volunteers. Positive changes were seen like smoothness, firmness and reduced wrinkles all leading to re-emergence of newer skin<sup>8,12,13</sup>. Topical antiaging agents containing alphahydroxy acids and antioxidants have been proved more beneficial antiaging agent by the studies of Kumari et al., and Watson et al<sup>14,15</sup>.

Besides the epidermis the beneficial effects are also seen in the dermis of skin showing increased bundles of collagen fibers in experimental group as compared to controls. No effect is found to be permanent all are temporary only during the period of treatment with antiaging agent. Glycolic acid is nowadays frequently used in different cleansers, toners, moisturizers and masks. Commonly available agents are combination of two or more antiaging agents producing enhanced response. The antiaging agent with some long lasting effects is the requirement of time and must be investigated by further studies.

## CONCLUSION

The epithelial thickness and collagen tissue are increased with the use of topical agent glycolic acid. These changes seem to be reversible.

## REFERENCES

1. Baumann, L., 2007. Skin aging & its treatment. *Journal of Path*; **211**(2):241-251.
2. Bhattacharyya, T. K., Thomas, J. R., 2004. Histomorphologic Changes in Aging Skin Observations in the CBA Mouse Model. *Arch Facial Plast Surg*; **6** (1): 21-25.
3. Bhattacharyya, T.K., Higgins, N.P., Sebastian, J.S., Thomas, J.R., 2009a. Comparison of epidermal morphological response to commercial antiwrinkle agents in the hairless mouse. *Dermatol Surg*; **35**(7):1109–1118.
4. Datta, H. S., Mitra, S. K., Paramesh, R., Patwardhan, B., 2011. Theories and Management of Aging: Modern and Ayurveda Perspectives. *Evidence-Based Complementary and Alternative Medicine*; **2011**:1-6.
5. Loden, M., Buraczewska, I., Halvarsson, K., 2007. Facial anti-wrinkle cream: influence of product presentation on effectiveness: a randomized and controlled study. *Skin Research and Technology*; **13**: 189–194.
6. Rachel, J.D. and Jamora, J.J., 2003. Skin Rejuvenation Regimens, A profilometry and histopathological study. *Arch Facial Plast Surg*; **5**(2):145-9.
7. Kornhauser, A., Wei, R.R., Yamaguchi, Y., Coelho, S.G., Kaidbeg, K., Barton, C., et al., 2009. The effects of

- topically applied Glycolic acid and Salicylic acid on ultraviolet radiation induced erythema, DNA damage and sun burn cell formation in human skin. *Dermatol Sci*; 55(1): 10-17.
8. Puizina-Ivic, N., Miric, L.C., Arija A., Karlica, D., Marasovi, D., 2010. Modern Approach to Topical Treatment of Aging Skin. *Coll. Antropol*; **34** (3): 1145–53.
  9. Junqueira, L.C. and Carneiro, J. 2010. Basic histology text and atlas. 12th ed. New York, McGraw Hill.
  10. Strandring, S., Collins, P., Wigley, C;2008. Gray's Anatomy, The anatomical basis of clinical practice. 40th ed. London: Churchill Livingstone Elsevier.
  11. Dhar, H.L., 2009. Approach to anti-aging. *Bombay Hospital Journal*; **51**(1): 68-72.
  12. Decker, A. and Graber, E.M., 2012. Over-the-counter Acne Treatments. *The Journal of Clinical and Aesthetic Dermatology*; **5**(5):32-40.
  13. Kraft, J. N. and Lynde, C. W., 2005. Moisturizers: What They Are and a Practical Approach to Product Selection. *Skin Therapy Letter*; **10** (5):1-8.
  14. Kumari, R. and Thappa, D.M., 2010. Comparative study of trichloroacetic acid versus glycolic acid chemical peels in the treatment of melasma. *Indian J Dermatol Venereol Leprol*; **76**(4):447.
  15. Watson, R.E.B., Ogden, S., Cotterell, L.F., Bowden, J.J., Bastrilles, J.Y., Long, S.P., et al., 2009. A cosmetic 'anti-ageing' product improves photoaged skin: a double-blind, randomized controlled trial. *Br J Dermatol*; **161**(2): 419–426.